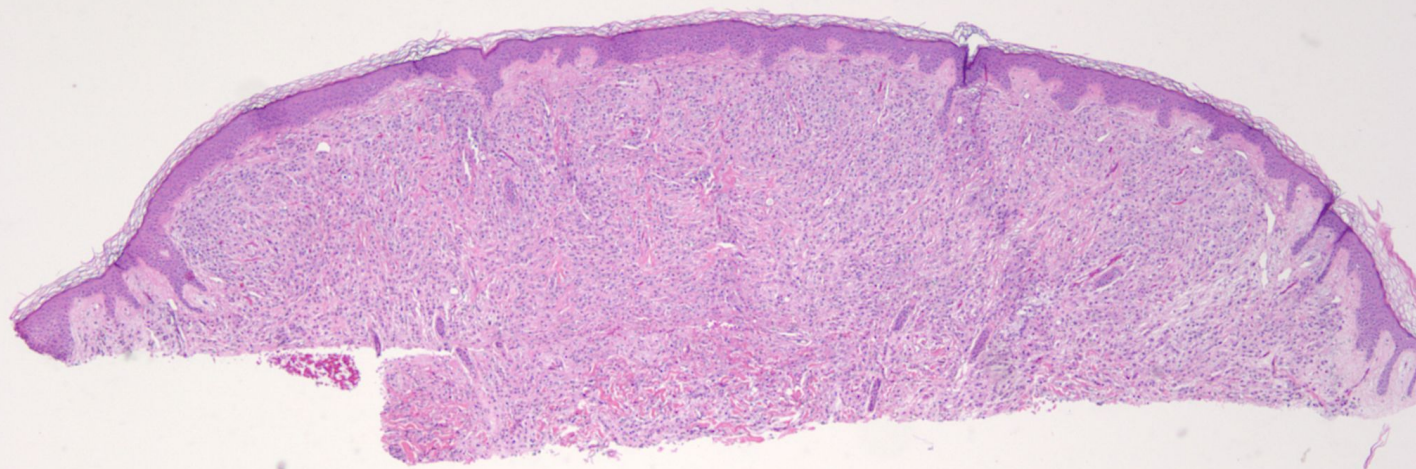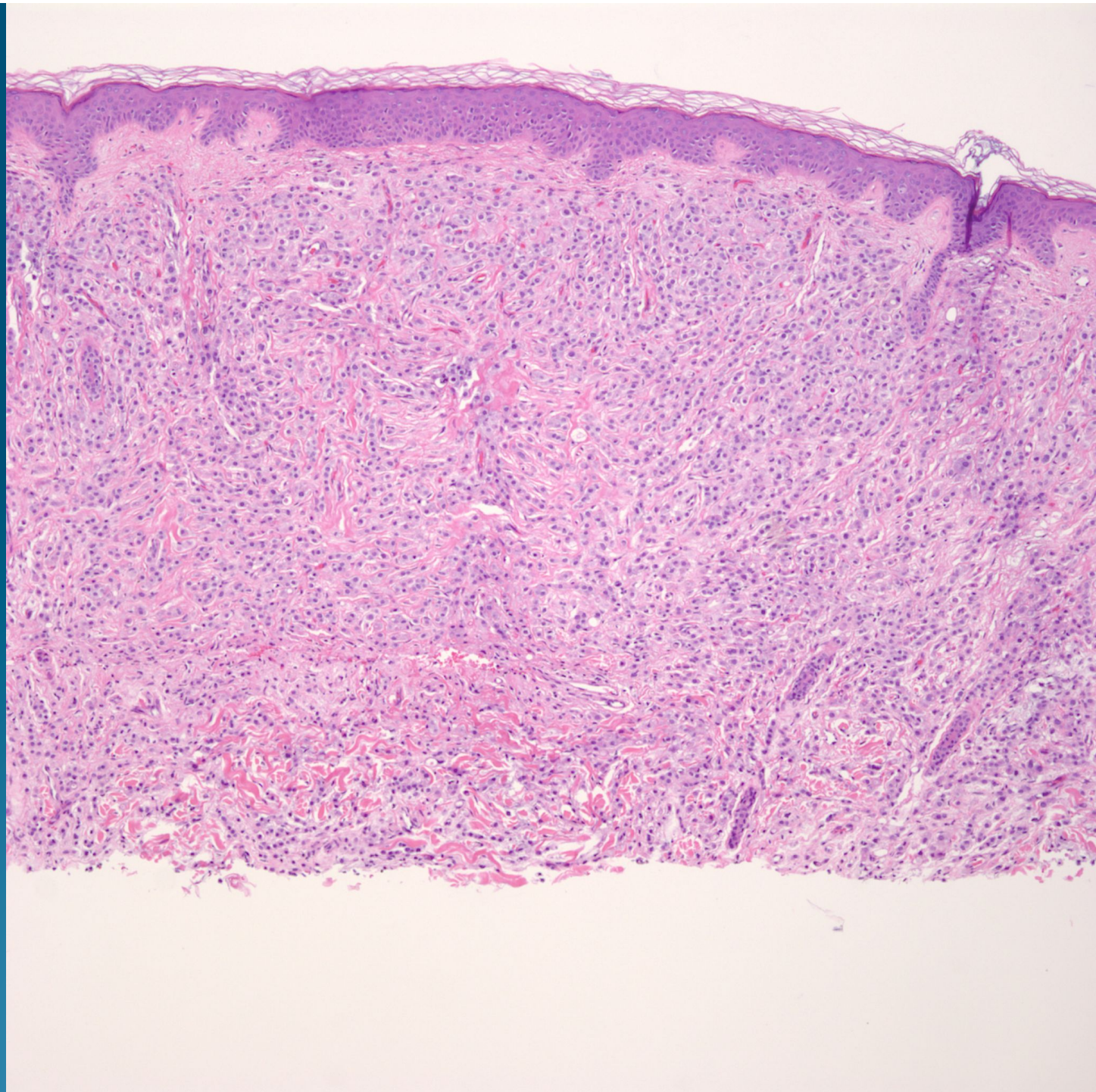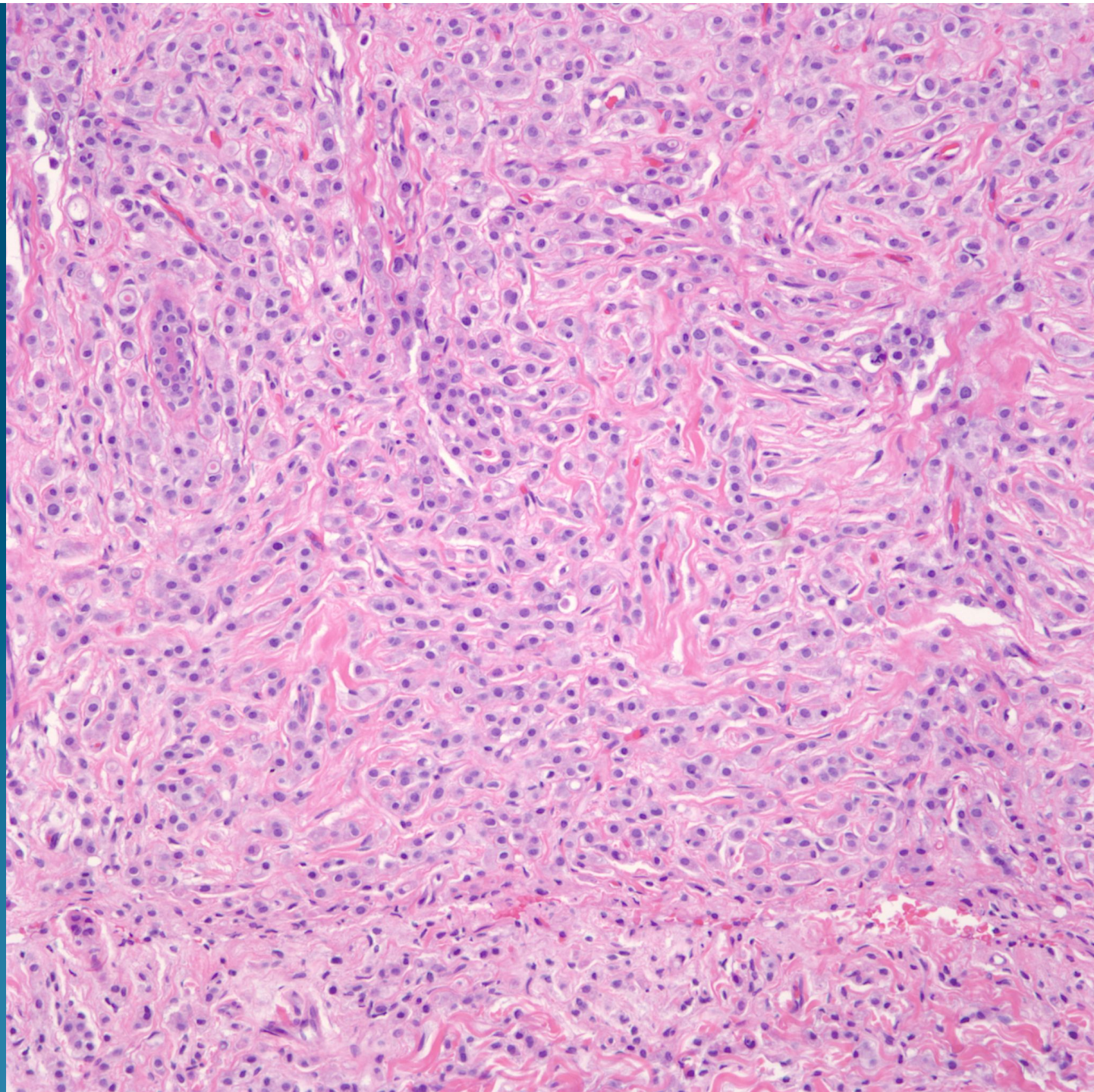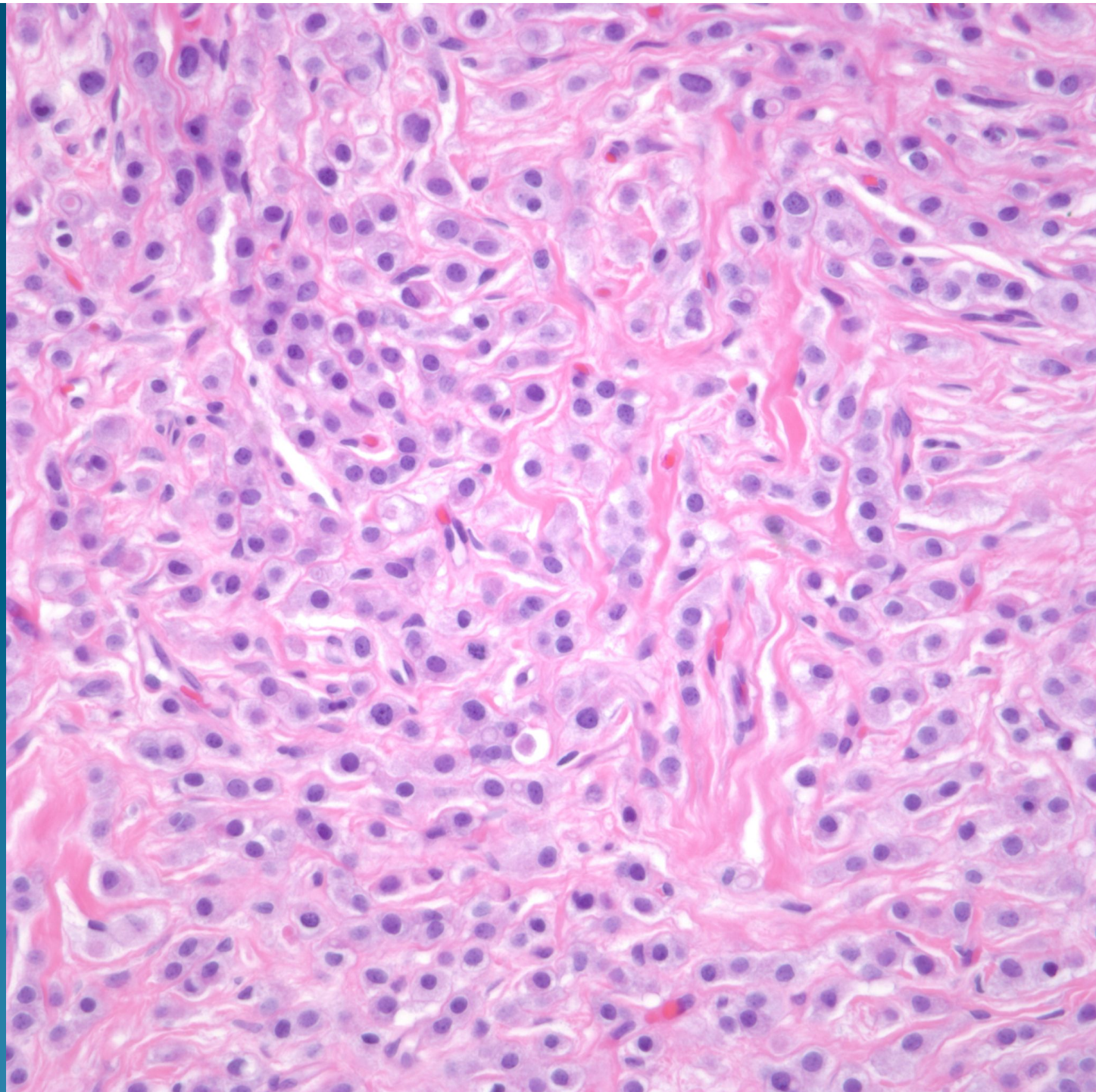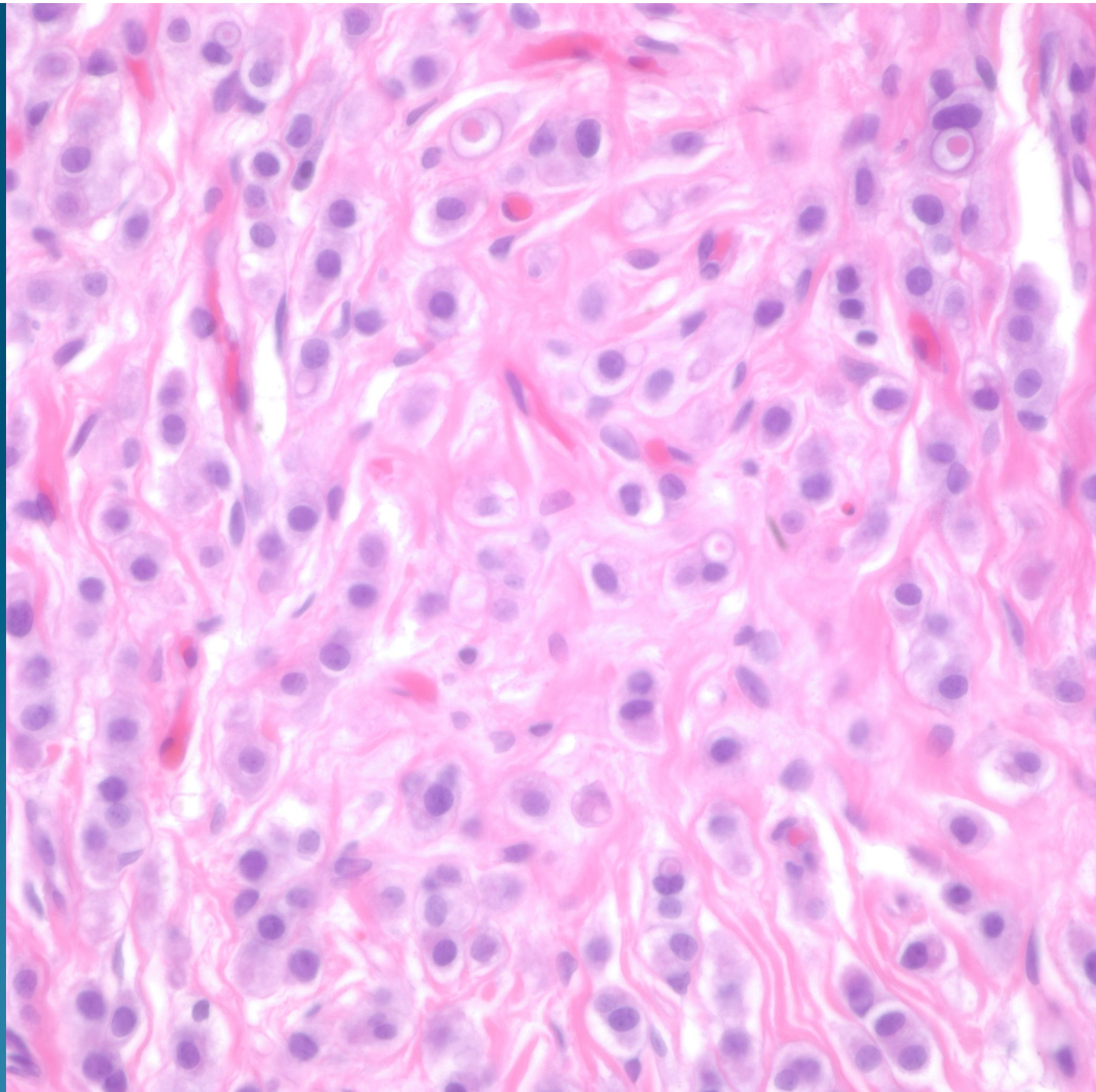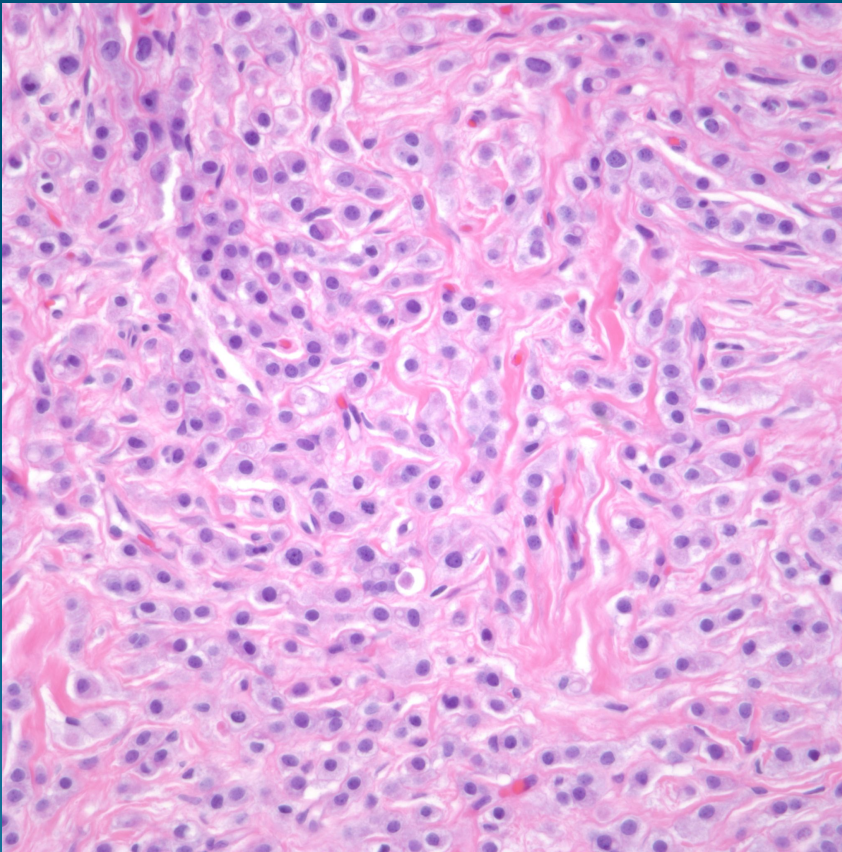


What is the best diagnosis?

- A. Chondroid syringoma
- B. Metastatic lobular carcinoma of the breast
- C. Malakoplakia
- D. Leishmaniasis
- E. Histoplasmosis

Metastatic Lobular Carcinoma of the breast

Pearls



- Sheets and linear infiltrating strands of epithelial cells
- Many cells may show a signet ring configuration
- Usually minimal cytologic atypia and minimal mitotic figures
- May need estrogen and progesterone receptors to distinguish from metastatic signet ring adenocarcinoma
- Always obtain history-there is a rare primary cutaneous signet ring adenocarcinoma of the skin